

Algivon® on Venous Ulcer

Elad A. Koren, RN, Head of the Israeli Wound Care Management and Research Association
Leumit Health Services, Geula, Jerusalem

Background

A 78 YO female from an ultra-orthodox community presented with a large superficial yellow-slough venous ulcer on her medial ankle, around 11 months since onset.

She was previously treated in three separate clinics with antibiotic creams, and IV antibiotics in two different hospitals.

Methods

We offered a totally different approach aiming at the vascular system.

We commenced daily dressing changes using Algivon, together with compression therapy.

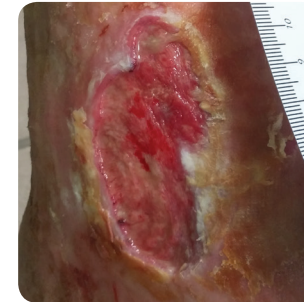
Conclusion

For the duration of 134 days of treatment the wound kept a good healing pace of 4.253 mm² a day.

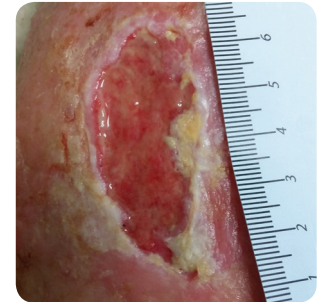
Even though the initial size was large and persistent for over ten months, clean wound bed was achieved within 14 days with full epithelization at the day of discharge.

The treatment is simple and can be self implemented, if necessary.

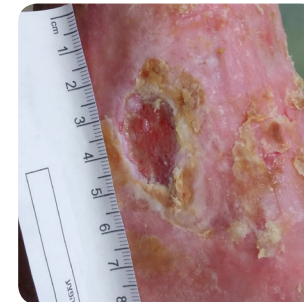Case Study



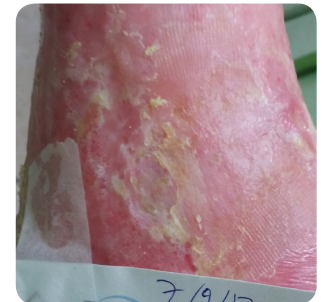14 days after presentation



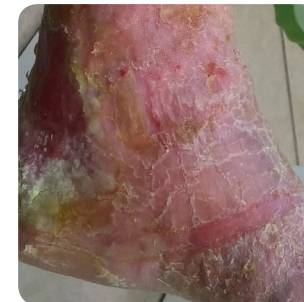42 days after presentation



70 days after presentation



123 days after presentation



134 days after presentation