

Reducing the need for oral antibiotics in head and neck cancer surgical wounds

Inger Jensen , ENT Assistant Nurse – Helsingborg Hospital, Sweden.

Aim

To reduce the amount of oral antibiotics use in patients with complex head and neck cancer wounds and to prevent or treat infections by utilising Manuka Honey dressings.

Method

Initially 3 patients were studied to test the hypothesis that Manuka Honey* would be as effective as oral antibiotics in preventing and treating wound infections in line with antimicrobial stewardship programme in the clinic. Patients were often referred from other clinics using other types of dressings. A different treatment would benefit the patients and Manuka honey was chosen.

Results / Conclusion

Without the need for oral antibiotics and choosing a topical antimicrobial these complex wounds healed effectively. All healed in 1-3 months with an average of 20 dressing changes. No oral antibiotics or further operations were needed. Antimicrobial stewardship in a small practice was effective, patients were pleased with the results and a reduction in the need for other medication. This small study has enabled the introduction of Manuka Honey as an alternative treatment and has gained interest from other clinics in Sweden to start utilizing Manuka Honey.

Case Studies

Case 1

72-year-old female, 15-month follow-up after therapy for carcinoma of the floor of the mouth, left side T4N1M0. She received surgery for her cancer and was reconstructed with a fibula graft and went through post operative radiation therapy. Her skin underwent necrosis that was treated with a radial forearm flap. The fibula graft also underwent necrosis, and she had a bleeding episode. A mandibular swing approach with a pectoral flap was performed.

The patient presented to the author for treatment 5 days post final surgery with a necrotic graft (Fig 1).

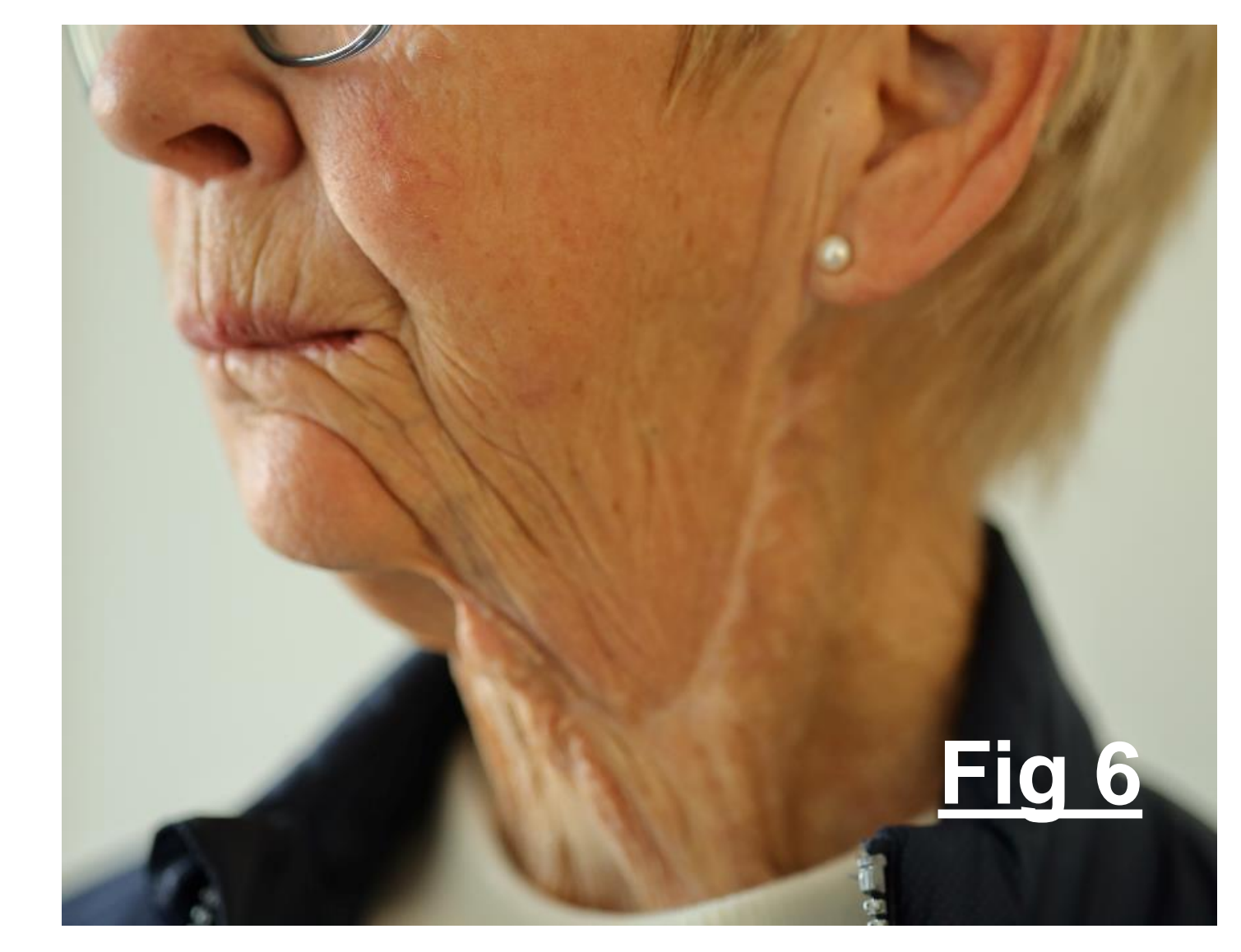
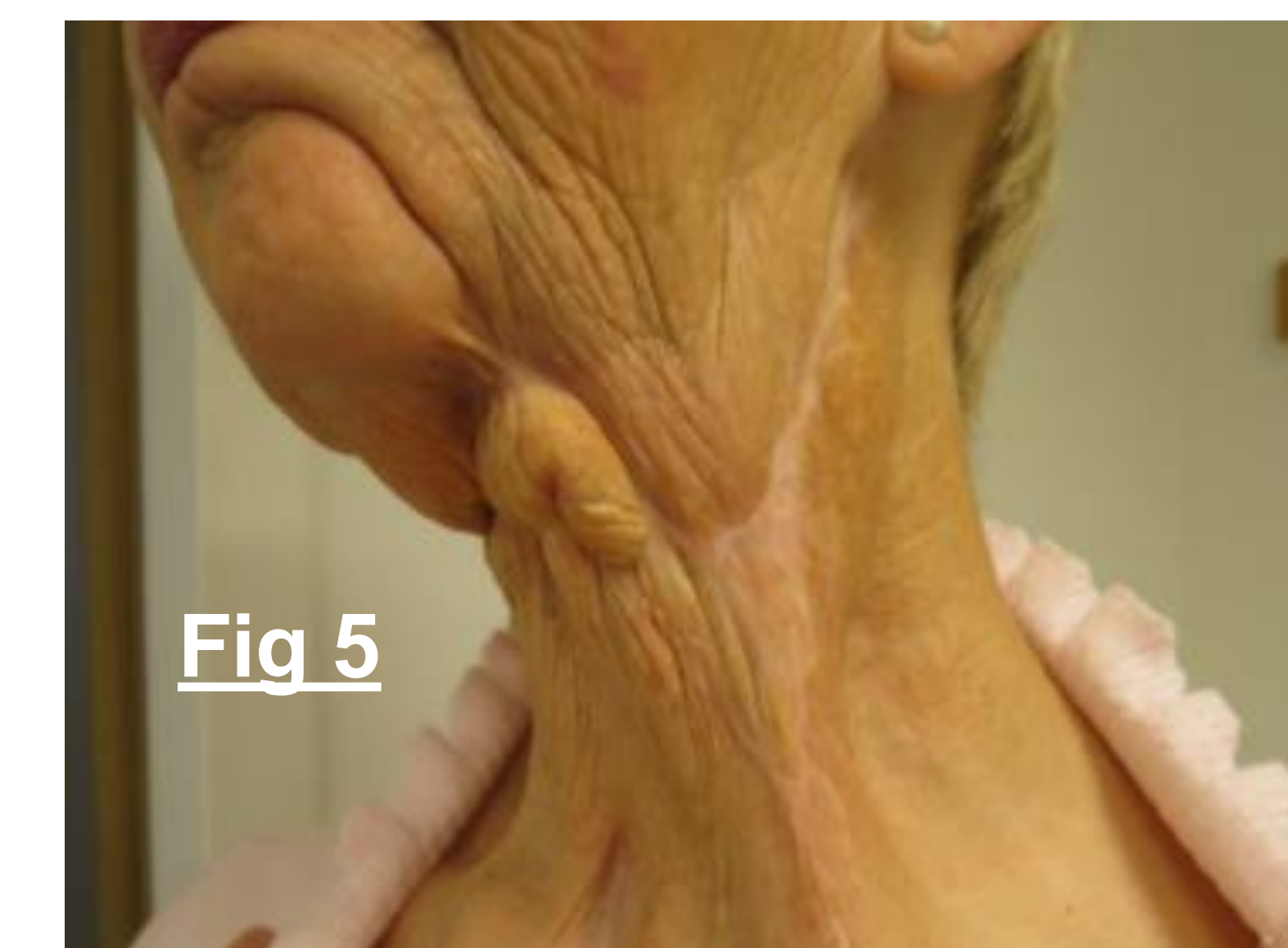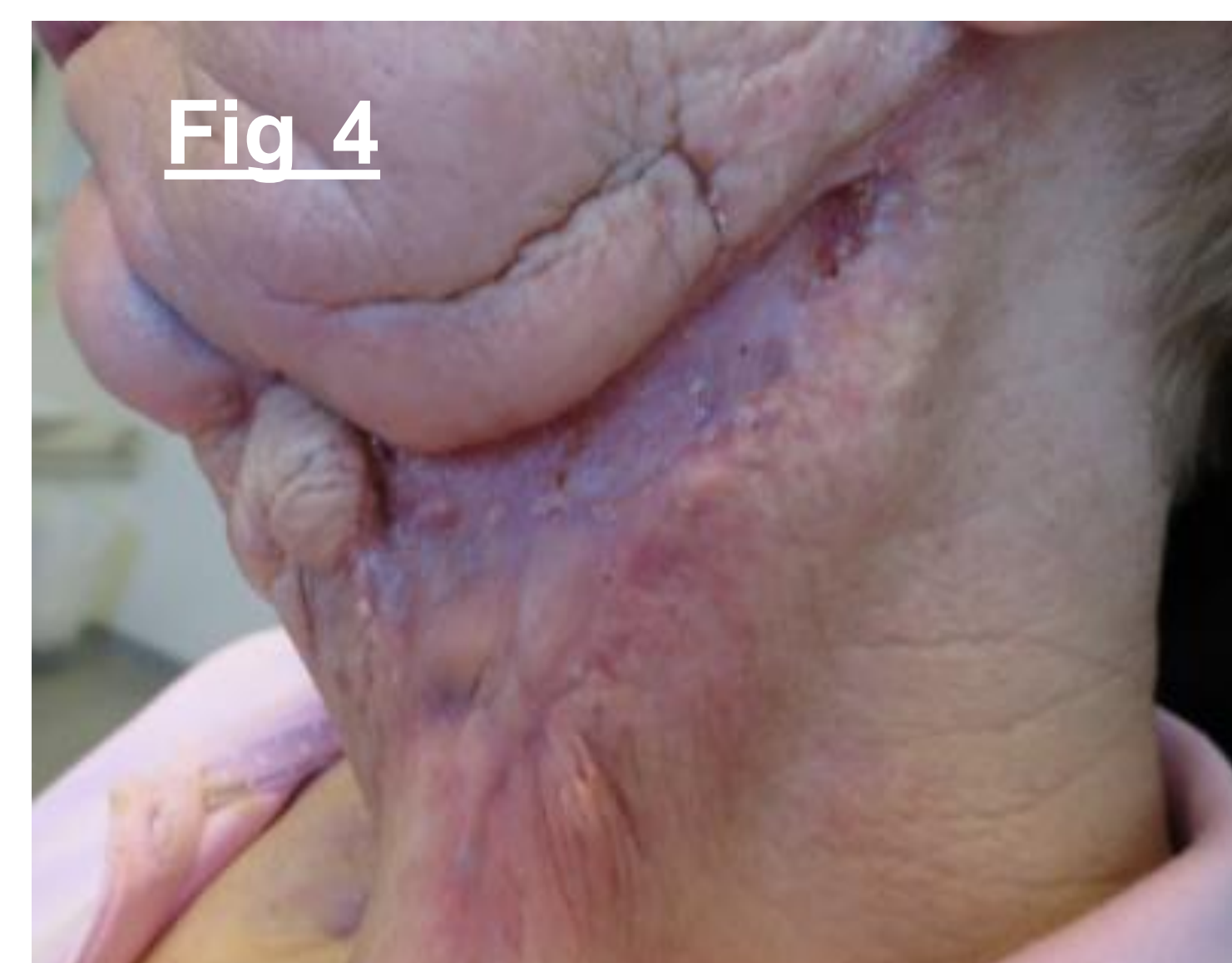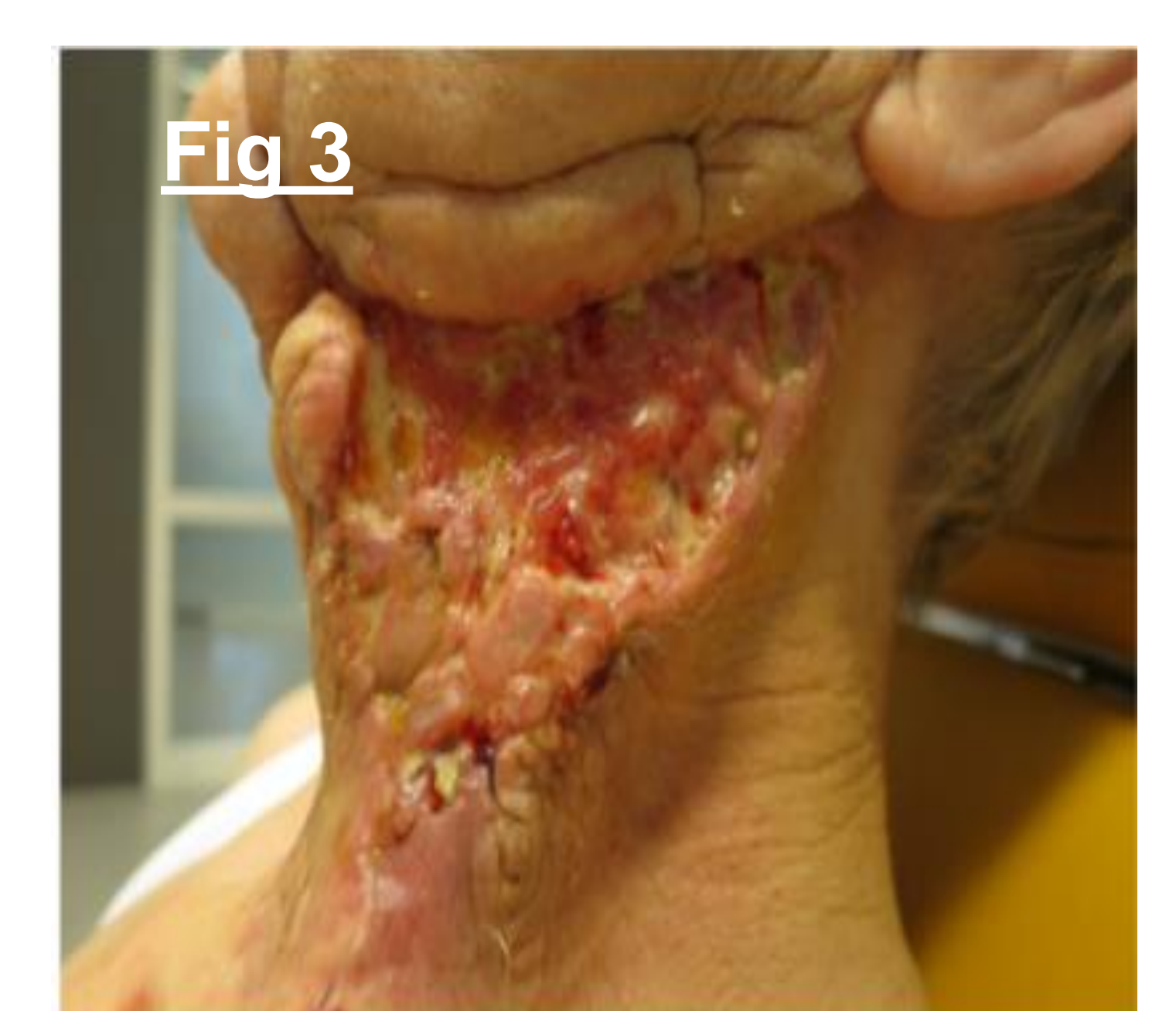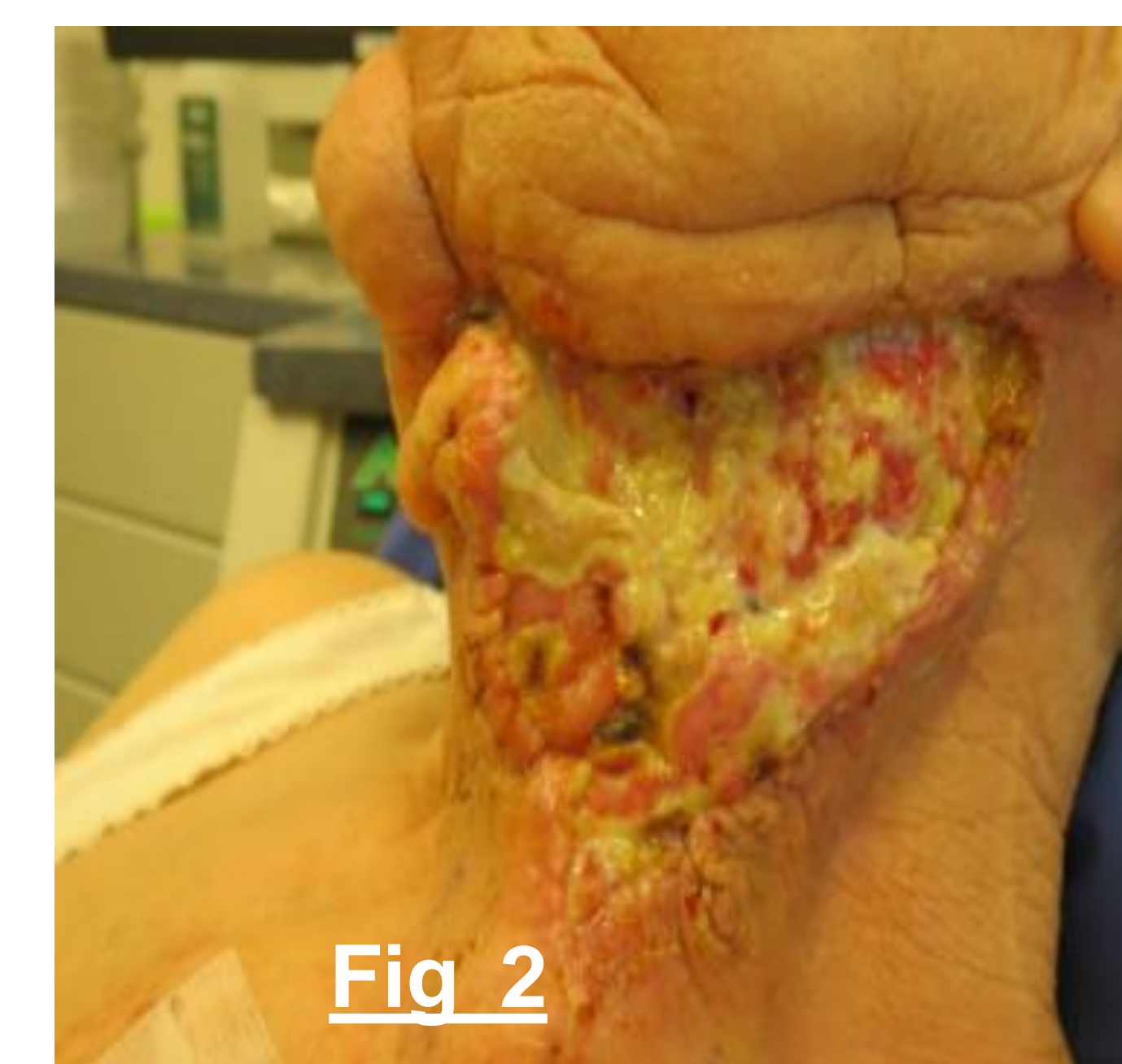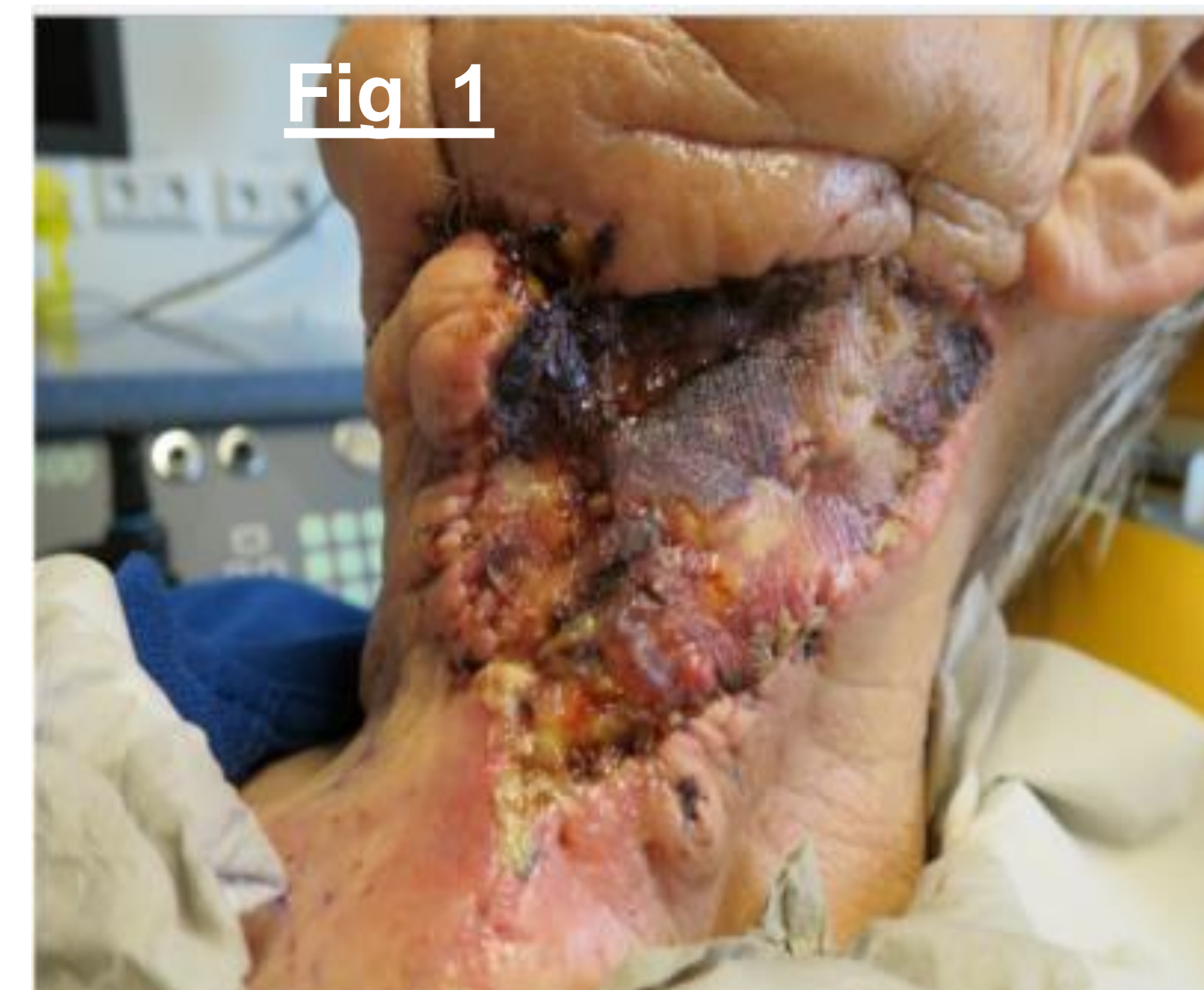The wound odor was mild with a lot of tissue necrosis. 100% Manuka Honey Viscose¹ and a Manuka Honey Viscose net³ were applied with a secondary dressing of an absorbent foam dressing⁴ Fig 2 - 2 days after starting with the honey treatment Odour was gone. Some sharp debridement was performed on this occasion only.

Fig 3 - 7 days post first dressing. Dressing changes took place every two days for 2 weeks, were reduced to twice a week for one week and were then performed weekly.

Fig 4 - 5 weeks post presentation the wound had healed with a total of 11 dressing changes. There was a surgeon appointment to arrange for a new graft for the skin defect, but no more surgery was needed.

Fig 5 - shows 12 months post treatment. The patient was extremely satisfied with the result and quick healing of this complex wound and did not need for any further medication or surgery.

Fig 6 - I met the patient in January this year. She did have one more surgery. Plastic surgery to reduce the big lump, to make the result perfect. She is really satisfied and enjoying life.



Case Studies

Case 2

49-year-old, otherwise healthy male with a lentigo malignant melanoma was presented to the author following a split thickness skin (fig 6). The wound measured is 7 x 7 cm

On presentation there was mild wound odour, and a large part of the skin graft was loose at the edges and sticky. There had been a postoperative bleed in the wound after the operation despite adequately applied pressure. The goal was to heal without additional surgery.

100% Manuka Honey² and a Manuka Honey Viscose Net dressing³ was applied on presentation. Fig 7 shows wound at 7 days after initial treatment after one dressing use.

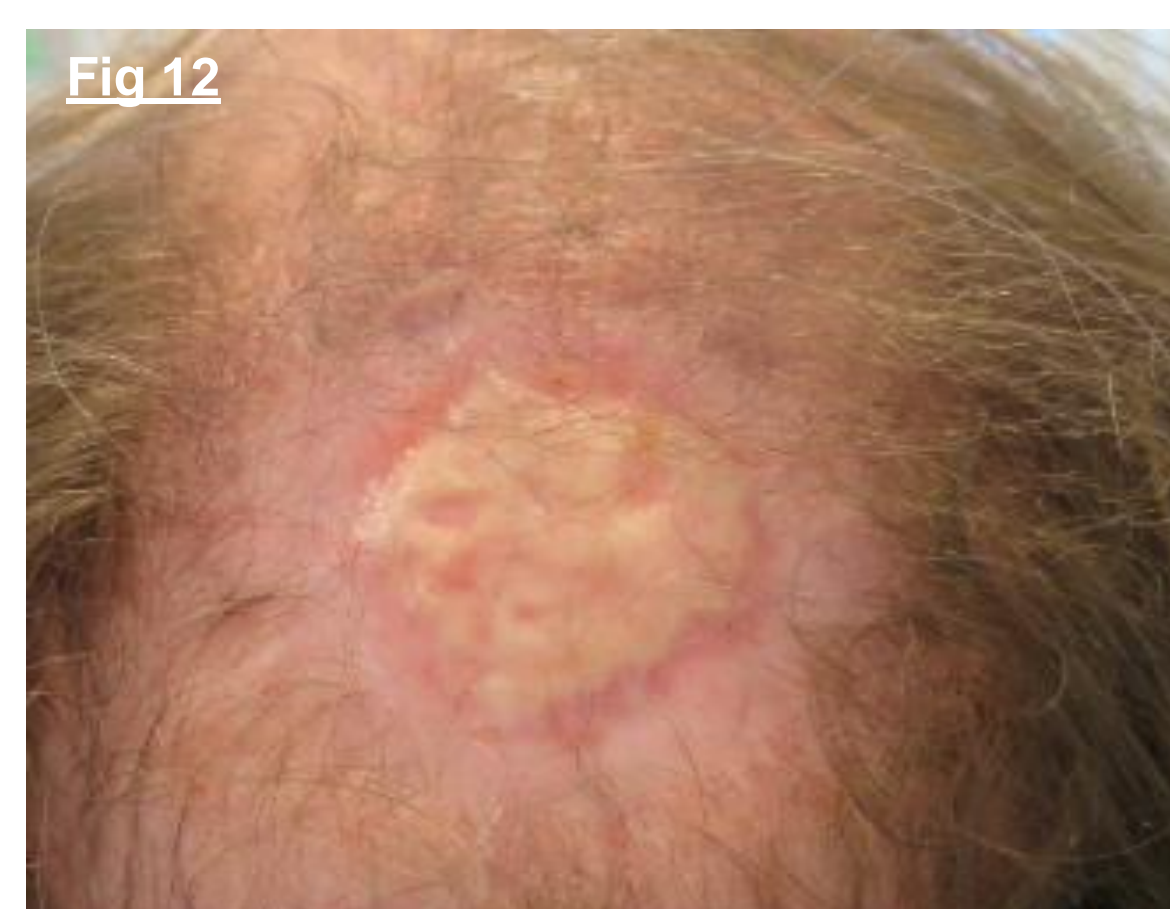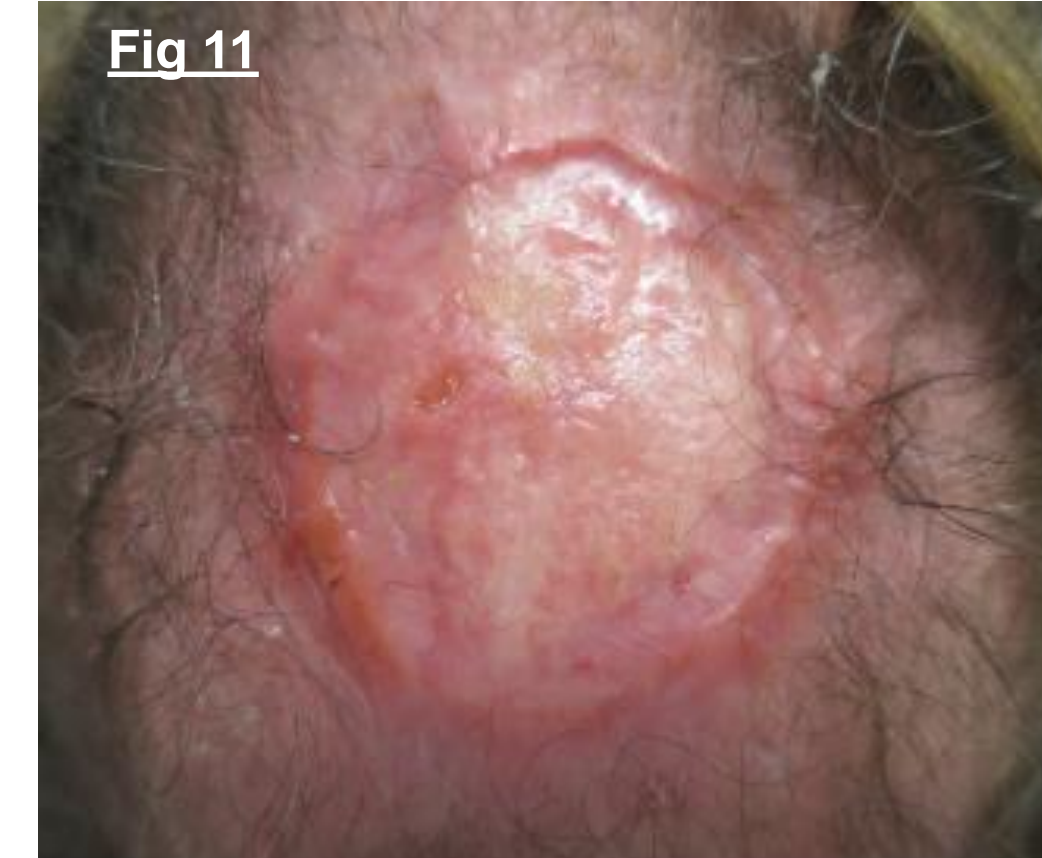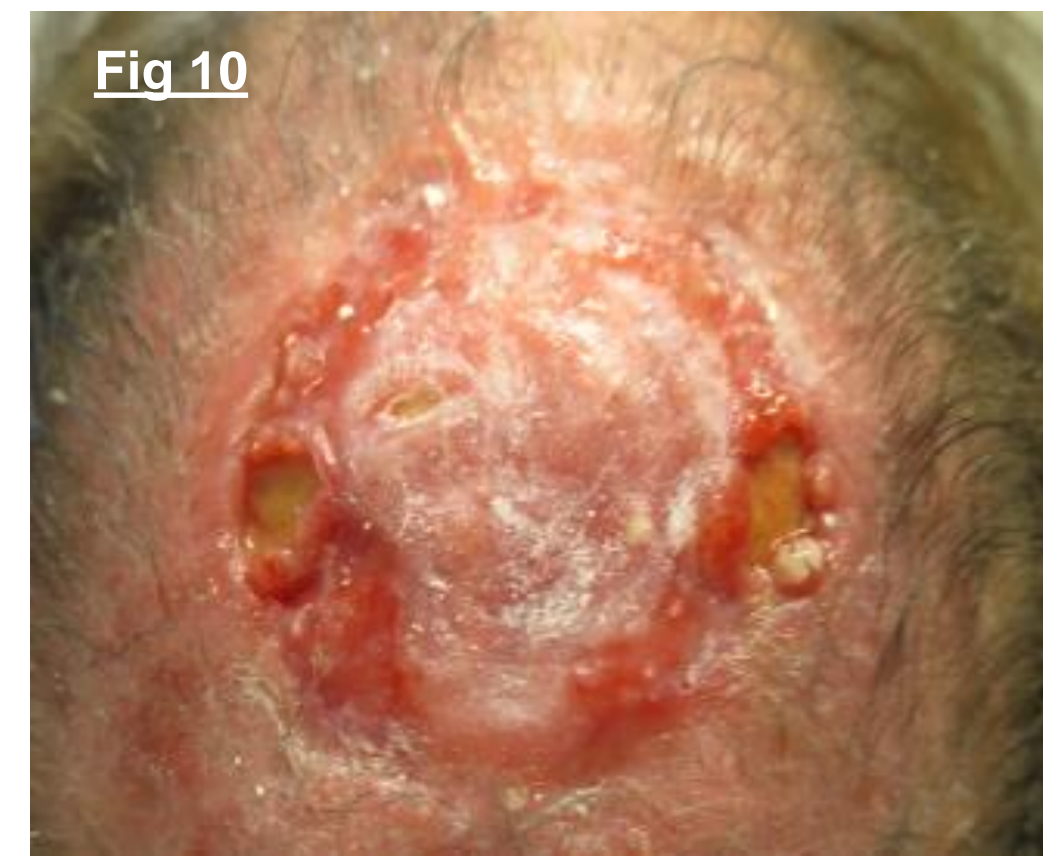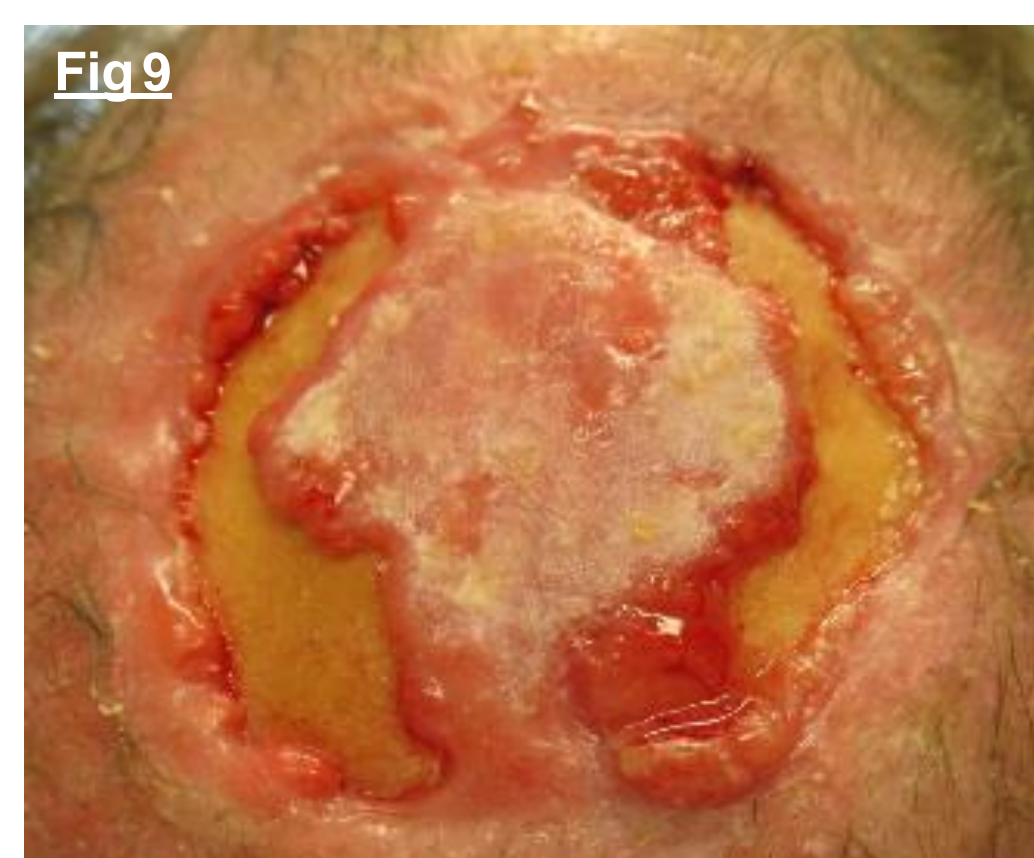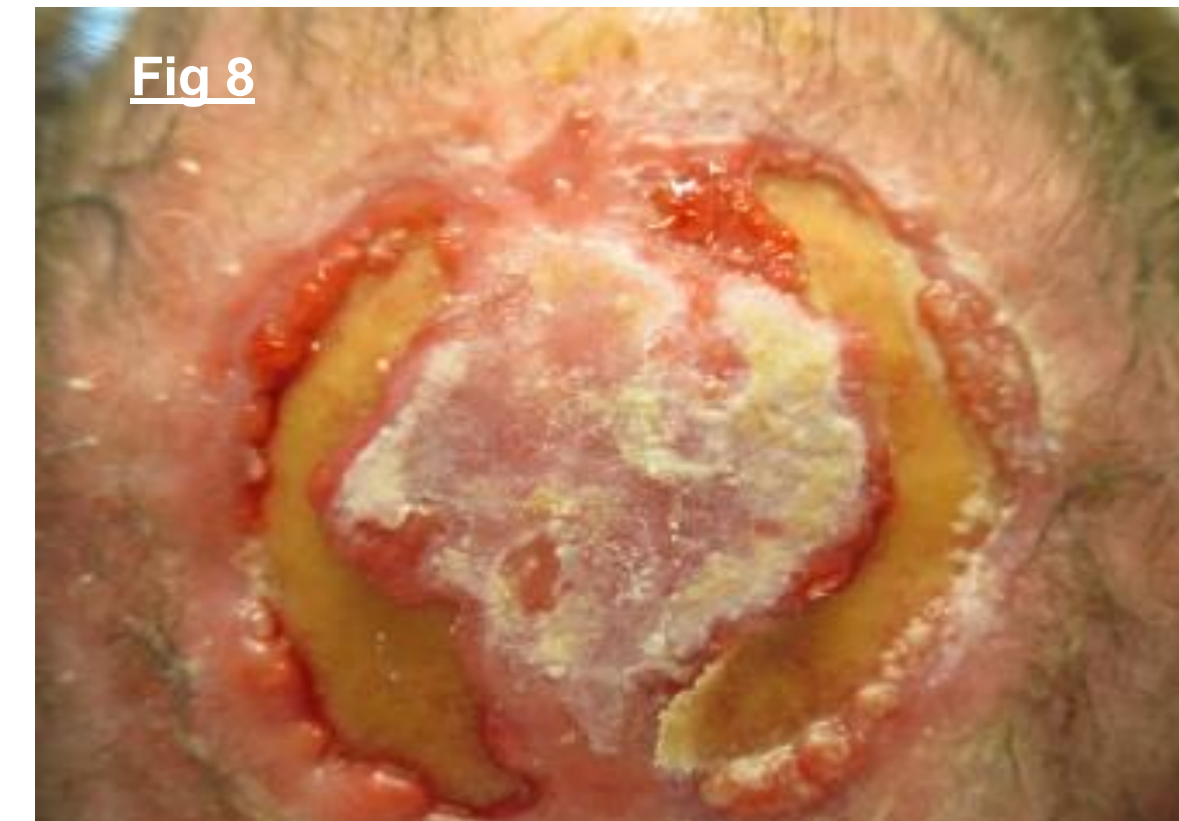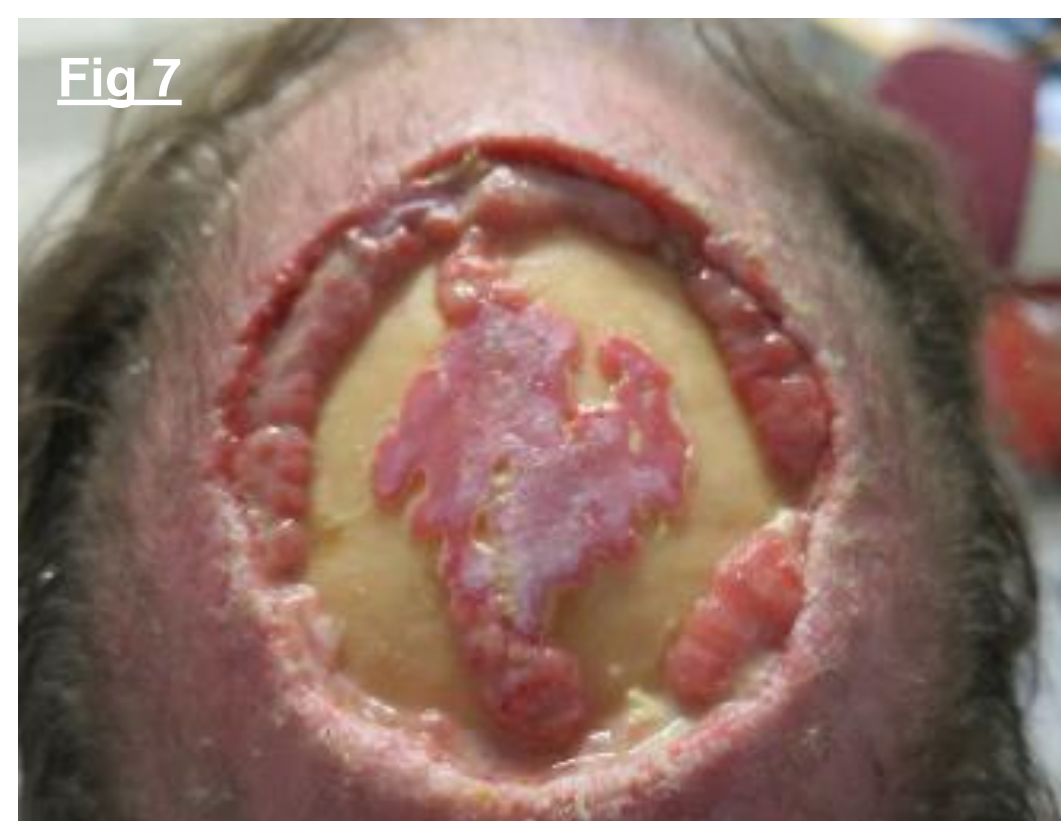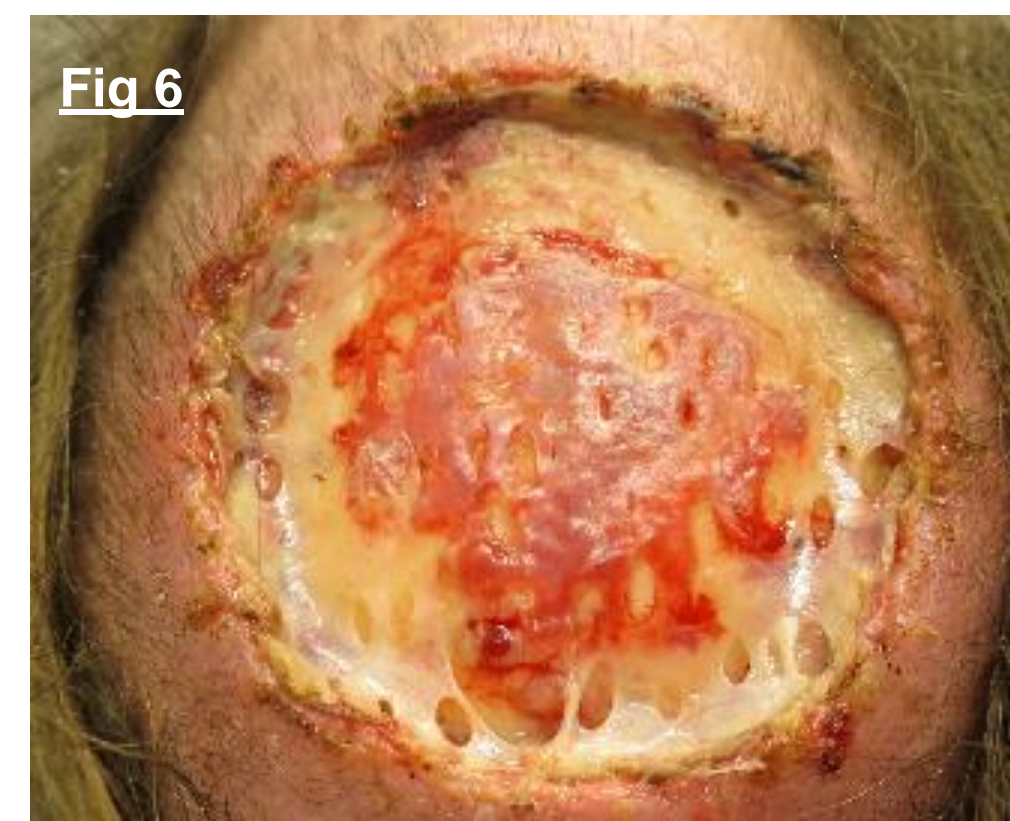Fig 8 and 9 show 2-month post presentation. There is a part of the hard periosteum that is dissolving.

This easy to breaks off and there is new fresh tissue underneath.

Manuka Honey Viscose Net³ and Activon tube was applied with an absorbent foam as a secondary dressing. Zinc paste was applied to the wound edges and to the new skin granulation tissue for protection from moist. Dressings were changed every three to four days in the first 6 weeks and were then once per week thereafter.

Fig 10 shows after three months with 100% Manuka honey² and Manuka Honey Viscose net³.

Four months after commencing treatment the patient was healed(fig 11). Fig 12 shows 1 year after surgery.



Case 3

74-year-old male, with type 2 diabetes controlled with Insulin and oral medication, pollen allergy. Presents with squamous cell carcinoma at the top of the skull. Receives surgery for carcinoma, and wound is left to heal by secondary intention.

First dressing change 5 days post-op (fig 13). There was odour and some irritation on the surrounding skin. Zinc paste was applied to the wound edges and 100% Manuka Honey² to the exposed bone

Two days later the odour was gone, and the skin condition improved (fig 14)

17 days later (fig 15) with only 100% Manuka Honey² and an absorbent dressing, the bone was covered with granulation tissue. Epithelialization is evident after 32 days (fig 16).

After a total of 26 dressings and 15 weeks the wound was healed (fig 17). Patient was very pleased with the results, he liked the idea with honey, because he always suffered with a bad stomach when taking oral antibiotics. He was surprised that this big wound became almost invisible when healed.

