

Silflex has unique Silfix Technology designed to minimise trauma associated with dressing change.


Silfix Technology

Silfix Technology ensures that Silflex gently adheres to the skin surrounding a wound, and not to the wound bed itself, to minimise the pain and trauma associated with dressing application and removal.

Managing pain associated with dressing change is a key priority to improve patient quality of life.



Silflex



Ordering codes and prices

Product	Stock code	Size	Pack Size	PIP Code	NHS SC Code
Silflex	CR3922	5cm x 5cm	10	338-4385	EKH028
	CR3923	8cm x 10cm	10	338-4393	EKH029
	CR3924	12cm x 15cm	10	338-4401	EKH030
	CR3925	20cm x 30cm	10	338-4419	EKH032
	CR4006	35cm x 60cm	5	338-2205	EKH096
Siltape	CR3938	2cm x 3m	1	344-0336	EHR053
	CR3939	4cm x 1.5m	1	344-0328	EHR054
Vellafilm	CR3919	12cm x 12cm	10	338-4351	N/A
	CR3921	15cm x 20cm	10	338-4369	N/A
	CR3917	12cm x 35cm	10	338-4377	N/A
Advasil Conform	CR3845	10cm x 10cm	5	301-1640	EKH006
	CR3832	10cm x 15cm	5	329-5979	ELY178

Get in touch

+44 (0)1623 751 500

info@advancis.co.uk

Find us online



www.advancis.co.uk

References

1. Edwards J, Mason S A. Developing a structured process for evaluating burn dressings. Poster presentation.
2. Holden-Lund C (1987) Effects of relaxation with guided imagery on surgical stress and wound healing. Res Helath Nurse 11(4):235-44
3. Advancis Medical Silflex range vs comparable products in Urgo Medical Urgotul range. Prices correct January 2022 – Drug Tariff

Silflex and Silfix Technology are trademarks of Brightwake Ltd. Contact info@advancis.co.uk for more information.

Silflex Soft Silicone Contact Layer

- ✓ Pain-free dressing changes
- ✓ Easier exudate management
- ✓ Superior handling



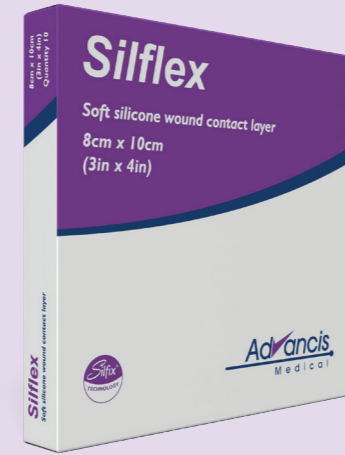
Silflex



Pain-free Dressing Changes


Pain during dressing changes can have a detrimental effect on patient Quality of Life (QoL)

Silflex scored better than an alternative silicone contact layer on mean pain scores at application, in situ and removal.¹



Easier exudate management

Unique 2mm pore holes allow passage of exudate into the secondary dressing, reducing maceration caused by exudate sitting against the skin.

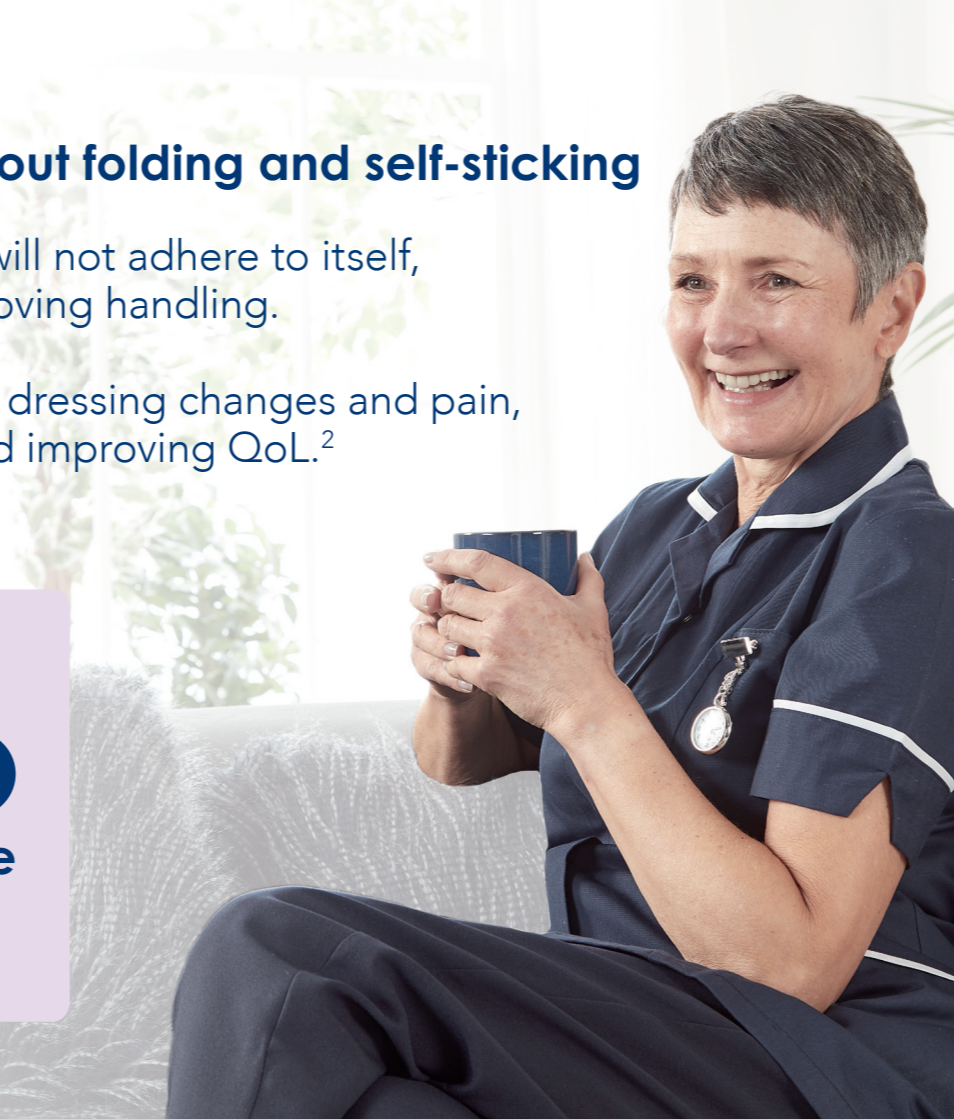

Superior handling without folding and self-sticking

Silflex is double sided, but will not adhere to itself, reducing wastage and improving handling.

A 14-day wear time reduces dressing changes and pain, reducing patient anxiety and improving QoL.²

19%
more cost-effective
than the market
leader³



Silflex used to treat a Skin Tear

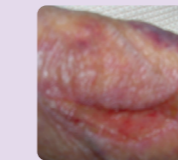
Patient Profile

Patient
89-year-old woman who presented with very dry, friable paper-thin skin and tissue.

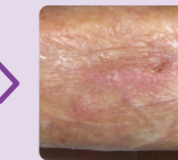
Wound
Skin tear measuring 3 x 0.8cm to right forearm with no viable tissue to reapply. Dry and intact with no evidence of infection.

Treatment
Due to the nature of the wound and concerns for the integrity of the surrounding skin, **Silflex** was applied and secured with a secondary dressing pad ensuring that there were no tapes or adhesives that would cause skin stripping on removal.

Results
Over a treatment period of three weeks, which included six dressing changes, this patient's skin tear had completely healed. **Silflex** was non-adherent and pain-free even on extremely friable tissue.



Presentation



Week 3

Silflex being used with a skin graft donor site

Patient Profile

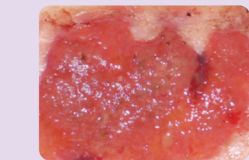
Patient
91-year-old woman

Wound
Longstanding leg ulcer which has taken a skin graft six months before referral. The skin graft had not been successful and the donor site had failed to heal completely leaving an area of hypergranulation.

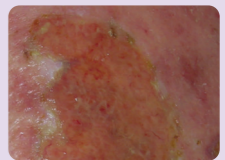
Previous Treatment
Hypergranulation was treated with nanocrystalline silver for 4 weeks but the wound was painful and bled when touched

Treatment Aim
The decision was taken to treat the hypergranulation with Terracortil ointment while protecting the fragile new epithelium which covered the remainder of the donor site with **Silflex**.

Results
After eight days and eight dressing changes the hypergranulation had resolved and the periwound area remained intact. The patient reported no pain or trauma at dressing changes.



Presentation



Day 8